Vascular anastomosis location in the left mediastinal space creates an anatomical barrier between vascular anastomoses and esophageal anastomosis, with its high potential risk of septic complications on the neck area. Level selection for vascular anastomosis depends on the colic vascular anatomy. It usually extends from rib II to IV. Based on our data, the technical possibility of vascular interarterial anastomoses formation is confirmed and also illustrates some of the technical difficulties in clinical practice. This study serves as a prototype for surgery on patients with esophageal diseases, notable cancer, requiring esophageal replacement. The proposed variant of vascular augmentation provides an adequate blood supply to the colonic graft and reduces ischemic complications postoperatively, confirming its value in this particular type of reconstructive surgery. The study of different methods of revascularization of intestinal autografts will help to reduce morbidity and mortality in these patients.

References

1. Yasuda T., Shiozaki H. Esophageal reconstruction with colon tissue. Surg Today. 2011; 41: 745–53.
2. Awsakulsutthi S. Result of esophageal reconstruction using supercharged interposition colon in corrosive and Boehave's injury: Thammasat University Hospital experience. J Med Assoc Thai. 2010; 93: 303–6.
3. Saeki H, Morita M, Harada N. et al. Esophageal replacement by colon interposition with micro vascular surgery for patients with thoracic esophageal cancer: the utility of superdrainage. Dis Esophagus. 2013; 26: 50–6.
4. Farran Teixidor L. Viñals Viñals JM, Miró Martín M. et al. Supercharged ileocoloplasty: an option for complex oesophageal reconstructions. Cir. Esp. 2011; 89: 87–93.
5. Kesler KA, Pillai ST, Birdas TJ. et al. "Supercharged" isoperistaltic colon interposition for long-segment esophageal reconstruction. Ann Thorac Surg. 2013; 95: 1162–8.
6. Ilyin IA, Malkevich VT, Podgayskiy AV. Otsrochennaya ezofagokoloplastika v lechenii raka pishchevoda i gastroezofagealnogo raka. Povolzhskiy onkologicheskiy vestnik. 2014; 3: C. 27–34.

BOOK REVIEW

Clinical Breast Tomosynthesis - a Case-Based Approach

Lonie Salkowski and Tanya Moseley. Published by: Thieme Publishers New York/Stuttgart. 2017, 272 pp, 420 illustrations, ISBN: 9781626231474



Numerous articles have been published over the last decade demonstrating the improved diagnostic accuracy of digital breast tomosynthesis (DBT) compared to convention 2D digital mammography (2DDM) and DBT is now being implemented in diagnostic breast imaging practices across the United Kingdom. There remains an ongoing debate regarding the use of DBT for routine breast cancer screening. Clinical Breast Tomosynthesis is a case based teaching atlas which reflects the extensive experience of breast imaging of Professors Lonie Salkowski and Tanya Moseley in their renowned breast diagnostic centres in North America. This comprehensive textbook is therefore is a welcome addition to the currently available mammography texts which are illustrated primarily with 2DDM images.

The book is divided into eight parts. The first part contains a succinct account of the physics of DBT and a summary of the BIRADS Lexicon. The remaining sections of the book consist of groups of cases arranged according to the role played by DBT, e.g. further assessment required for an abnormality found on DBT screening, or DBT assessment following screening with 2D mammography. For each case there is a summary of the mammographic findings, a discussion of the differential diagnosis, a list of essential facts and relevant learning points and a short reference list. The mammograms are displayed with and without annotation, and further images including relevant tomosynthesis slices, spot compression views, ultrasound and MRI are included. The quality of the images is generally very good but in some cases very subtle soft tissue abnormalities or fine microcalcification are difficult to visualise and the quality could have been improved by further cropping and display of an enlarged image. The teaching value of this book is greatly enhanced by the inclusion of 238 videos of tomosynthesis examinations which are easily accessed online - for each case the tomosynthesis cine-loop can be viewed alongside the printed images and accompanying text.

Readers from the UK will note some differences in clinical practice compared to North America and may question the use of mammography in women in their thirties and the practice of six months follow up for probably benign lesions. This however should not detract from the quality of this excellent book which has been well written and comprehensively illustrated. It will be of particular value to breast diagnostic departments which are currently integrating DBT into their clinical practice.

Dr Michael J Michell
Consultant Radiologist, Breast Radiology Department, Kings College Hospital NHS Foundation Trust, Denmark Hill, London SE5 9RS,UK

Cutaneous malignancies: A Surgical Perspective

Brian R. Gastman (Editor). Published by: Thieme Publishers New York/Stuttgart. ISBN 978-1-62623-147-4

This 251 page hardback book was a pleasure to read. Thirty-two authors from different specialties within the USA have contributed, producing a comprehensive guide to the surgical management of skin cancer.

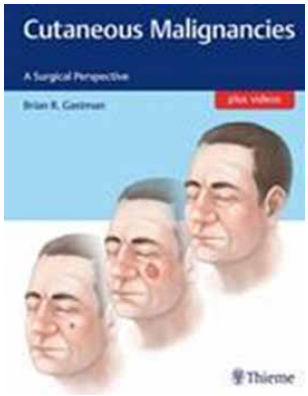

This book was written with the intent of assisting surgeons, first to consolidate the surgical methods of treating patients with cutaneous malignancies, and second to bring together non-surgical therapies of which, the surgeon needs to be aware. Successful treatment of skin cancers often requires a multidisciplinary approach, making this useful to clinical and medical oncologist in particular. Non-surgical doctors will find this book illuminating in that it explains the roles of surgery, including Moh's Micrographic surgery, sentinel lymph node biopsy, lymphadenectomy and surgical reconstruction in the often complex and challenging treatment protocols of some patients.

There are 12 chapters that provide access to online videos of 4 surgical procedures. The first chapter details the prevention of skin cancer in future, when to treat, refer and follow up, whereas the second discusses the clinical detection of cancer. Atlas quality clinical photographs are used throughout to illustrate different types of malignancies. The etiology, presentation, biopsy techniques, treatment approaches and surgical management are discussed in detail for SCC and BCC, again with the aid of photographs and diagrams. Chapters are devoted to the surgical treatment of melanoma and rare skin tumours. Mohs Micrographic Surgery's role in the treatment of skin cancer is brilliantly explained, as is the chapter on the role of radiotherapy in the treatment of skin malignancies. I enjoyed reading the chapters on reconstructive techniques after facial skin cancer excision; the flaps in common usage are demonstrated. Chapter 10, Operative Lymphadenectomy, discusses all aspects of sentinel node biopsy and operative lymphadenectomy, including neck dissection and selective nodal dissections.

The final chapter addresses the interesting problem of high-risk skin tumours. High risk groups include those with genetic syndromes that result in an increased predisposition to malignancies and immunosuppressed patients. The current body of knowledge is reviewed and strategies for treatment of such skin cancers are formulated.

In summary, I found this book to be readable and very informative. It is well written with hundreds of good quality photographs; it is evidence-based and well referenced. This book is a specialist text reflected in its price of £167.50

Dr Karin Baria
Retired Consultant Clinical Oncologist