Review of Minimally Invasive Video-Assisted Thyroidectomy in Thyroid Tumours

Ms Tawakir Kamani MD, MRCS, DOHNS, MSc,
Specialty Registrar Year 6, Department of Otolaryngology, Head and Neck surgery, Royal Derby Hospital Derby, UK.

Mr Mriganka De MBBS, FRCS,
Consultant Head & Neck Surgeon, Department of Otolaryngology, Head and Neck surgery, Royal Derby Hospital Derby, UK.

Correspondence:
Mr Mriganka De
18 Yewdale
196 Harborne Park Road
Birmingham B17 0BP
T: 0793202769
E: mrigankade@hotmail.com

In recent years, a move toward endoscopic surgery has occurred, one major advantage being cosmetic. Gagner et al. [1] initially described endoscopic parathyroidectomy in 1996, which led to further development in the technique, with minimally invasive video-assisted thyroidectomy (MIVAT) being first described by Husher et al. [2] in 1997, using a wall-lifter to perform thyroid lobectomy with lower pressure levels of CO_2 insufflation. The technique eliminated potential risks of CO_2 insufflation of hypercapnia, respiratory acidosis and subcutaneous emphysema [2,3]. Miccoli [4] confirmed the suitability of MIVAT by a 15-20mm transversal skin incision made 2cm above the sternal notch. Use of a harmonic scalpel has allowed cutting of tissues with simultaneous haemostasis and helped technically challenging thyroid surgery [5].

In the last decade, MIVAT has become more widespread, with several surgeons in Europe and Asia pioneering this technique. A number of different approaches have been identified to perform endoscopic thyroid, which include access through the breast, axilla, combined axillo-breast and central/lateral cervical neck approaches. The axillary and the breast approaches work on the principle of moving the scar away from the neck, but leaves an elongated dissection area with potentially increased scarring along its route, as well as an increased operating time [6]. The lateral neck approach has been used to address single-sided pathology for hemi-thyroidectomy, and the central approach allows for either or both sides of the thyroid gland to be addressed. This review aims to identify the role of MIVAT in neoplastic thyroid disease.

Surgical technique

This was originally described by Miccoli et al. [4]. The instruments used for MIVAT include surgical tools with small diameter: a-traumatic spatulas, spatula-shaped aspirator, forceps and scissors in addition to the conventional ones. The primary MIVAT tools are a 30-degree 5mm endoscope and a 14cm Harmonic Scalpel Scissors. Three surgeons are required to perform the surgery.

The patient is placed with moderate neck extended centrally placed in supine position. A gasless video-assisted technique is carried out through a 15mm midline incision. A high incision is made between the cricoid and sternal notch (Figure 1). Endoscopic dissection of the upper pedicle is carried out, with identification and preservation of the external branch of the superior laryngeal nerve, followed by endoscopic identification of the recurrent laryngeal nerve (RLN) and parathyroid glands (PG; see Figure 2). The lobe is then extracted and resected through the incision, and the wound is closed. A surgical drain is not usually required due to the minimal blood loss.

Discussion

Conventional neck surgery is considered an excellent standard in thyroid surgery with well established minimal complication rates and does not require detailed patient selection [4,7]. There is great scepticism about the advantages of MIVATS over conventional thyroid surgery, but this are may be unfounded as this technique is only offered to a small number of patients that fulfil its strict selection criteria. The indications and selection criteria, as well as contraindications for the choice of MIVATS in thyroid tumours, are given in Table 1 below.

There is increasing evidence with moderate to large series of patients operated on using the MIVATS technique described by Miccoli et al. [4], which allows an effective comparison with the traditional surgery described by Kocher [8,9].

The use of endoscopes gives surgical precision to the technique of MIVATS through improved lighting and magnification, resulting in an excellent view for the surgeon of structures to dissect and preserve, in particular the RLN and parathyroid glands. Limited and controlled dissection within the neck with hemostasis achieved in every step has led to a significant reduction in post-operative pain compared with conventional surgery [10]. The use of surgical wound drains is usually not required, making it suitable for day-case surgery. These results suggest MIVATS is a potential economical option with improved patient satisfaction. With limited wound size, the resulting post-operative scar is small (< 3cm) and cosmetically preferred. The size of the thyroid tissue to be removed is

Advocates of MIVAT suggest that it gives comparable results to conventional thyroid surgery, but with advantages of reduced trauma, better post-operative course, early discharge and improved cosmetic results

Figure 1: This shows the position and size of the scar.

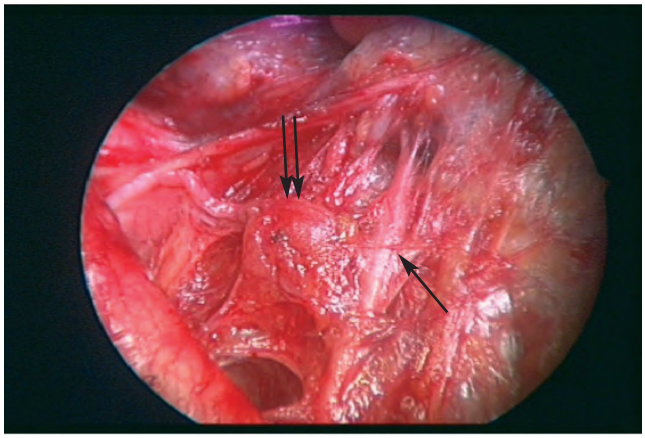

Figure 2: Endoscopic view of the Recurrent Laryngeal Nerve (single arrow) and the superior parathyroid (double arrow)

paramount, since there is no difference to conventional surgery in the wound size and resulting cosmesis beyond 50ml [10].

Alvarado et al. [11] demonstrated in their series of cases that the complication rates were comparable to conventional surgery. They found the rate of post-operative hematoma formation and wound infection was mush the same. The rate of permanent recurrent laryngeal nerve injury was 0.4% for MIVATS and 0.3% for conventional, which is not significantly different ($p = 0.7$). The series of patients reported by Terris et al. [9] showed temporary hypocalcaemia in 8.1% of all total thyroidectomy done by this method. No permanent hypocalcaemia was noted. With strict patient selection criteria adopted for consideration of MIVATS (Table 1), the conversion rate would be small. Miccoli et al. [5] found a rate of 4.5% in their series, mainly due to difficulty in dissection making important structures such as the RLN difficult to identify, and also due to hemorrhage.

Although an argument regarding a 'learning curve' exists, Miccoli et al. [4] have reduced operating time from 73.6 minutes to an average of 47 minutes, comparable with conventional thyroid surgery. It will be further reduced as the peak of the learning curve is reached [9]. There are also significant economic implications in using three surgeons for this procedure, one primary and two assistants being required.

These factors would not make an attractive economic option in an institute where the introduction of this technique would require increased initial staffing and a smaller through-put in a theatre list.

The case for malignancy being a contraindication for the use of MIVATS has been argued. Lombardi et al. [12] found that there was no additional risk of seeding with rupture of thyroid capsule than conventional surgery. Indeed, Miccoli et al. [4] found no clinical or radiological evidence of metastatic or recurrent thyroid cancer in their series. They did suggest central compartment dissection for these patients through MIVATS, but this is time-consuming. It is therefore thought to be a reasonable technique of choice for small follicular lesions confirmed by FNAC. This is particularly relevant to the young female patient who would prefer to have a minimal scar.

Summary and conclusion

Advocates of MIVAT suggest that it gives comparable results to conventional thyroid surgery, but with advantages of reduced trauma, better post-operative course, early discharge and improved cosmetic results. MIVATS does, however, show a learning curve with operative time now being reduced. Its use is also apparent in the treatment of 'low-risk' malignancies. With the current trend in increased day-case operating, it may well be that MIVAT will become an economically viable option in a carefully selected group of patients. Further studies comparing the experienced surgeon's surgical time in both MIVATS and conventional thyroid surgery would be useful information. ■

Table 1: Selection criteria for MIVATS suitable patients

Criteria for selection	Contraindications for MIVAT
Total thyroid volume 25-50 ml	Large thyroid volume over 50ml
Single nodule or small goitre (<7cm in cranio-caudal axis and <3.5cm in transverse diameter)	Big goitre
Small (max 2 cm) differentiated carcinoma without lymph node involvement	Previous neck radiation therapy: local advanced cancer; lymph node metastasis; medullary or undifferentiated carcinoma

References

1. Gagner M. *Endoscopic subtotal parathyroidectomy in patients with primary hyperparathyroidism.* Br J Surg. 1996;83:875.
2. H scher CS, Chiodini S, Napolitano C et al. *Endoscopic right thyroid lobectomy.* Surg Endosc 1997:11(8):877.
3. Naitoh T, Gagner M, Garcia-Ruiz A. *Endoscopic endocrine surgery in the neck: an initial report of endoscopic subtotal parathyroidectomy.* Surg Endosc. 1998;12:202-206.
4. Miccoli P, Berti P, Raffaelli M, Conte M, Materazzi G, Galleri D. *Minimally invasive video-assisted thyroidectomy.* Am J Surg 2001;181:567–70.
5. Barczy ski M, Konturek A, Cicho S. *Minimally invasive video-assisted thyroidectomy (MIVAT) with and without use of harmonic scalpel—a randomized study.* Langenbeck's Archives of Surgery. 2008;303:647-54.
6. Henry JF. *Minimally invasive thyroid and parathyroid surgery is not a question of length of the incision.* Langenbecks Arch Surg 2008;393(5):621-6.
7. Bellantone R, Lombardi CP, Raffaelli M, Rubino F, Boscherini M, Perilli W. *Minimally invasive, totally gasless video-assisted thyroid lobectomy.* Am J Surg. 1999;177:342–3.
8. Miccoli P, Bellatone R, Mourad M, Walz M, Rafaelli M, Berti P. *Minimally Invasive Video-assisted Thyroidectomy: Multiinstitutional Experience.* World J. Surg 2002;26:972–5.
9. Terris JD, Angelos P, Steward DL, Simental AA. *Minimally Invasive Video-Assisted Thyroidectomy, A Multi-institutional North American Experience.* Arch Otolaryngol Head Neck Surg 2008; 134 (1):81-4.
10. Miccoli P, Berti P, Raffaelli M, Materazzi G, Baldacci S, Rossi G. *Comparison between minimally invasive video-assisted thyroidectomy and conventional thyroidectomy: a prospective randomized study.* 2001;130(6):1039-43.
11. Alvarado R, McMullen T, Sidhu SB, Delbridge LW, Sywak MS. *Minimally invasive thyroid surgery for single nodules: an evidence-based review of the lateral mini-incision technique.* World J Surg 2008;32(7):1341-8.
12. Lombardi CP, Raffaelli M, Princi P, Lulli P, Rossi ED, Fadda G, et al. *Safety of video-assisted thyroidectomy versus conventional surgery.* Head Neck 2005;27(1):58-64.